


This affidavit is in compliance with Texas Rules of Criminal Evidence, Rule 902 (10b).  
 Case No. 3019-86-1413 Office of the Medical Examiner  
 in the matter of In the County of DALLAS  
Jason Cory GRAF, deceased State of TEXAS

AFFIDAVIT

Before me, the undersigned authority, personally appeared Betty J. Lones  
 \_\_\_\_\_, who, being by me duly sworn, deposed as  
 follows:

My name is Betty J. Lones, I am over 21 years of age, of sound mind,  
 capable of making this affidavit, and personally acquainted with the facts herein  
 stated:

I am the Deputy Custodian of Records of the Dallas County Medical  
 Examiner's Office. Attached hereto are 4 pages of records and xx photographs  
 from the Dallas County Medical Examiner's Office. These said 4 pages of records  
 and xx photographs are kept by the Dallas County Medical Examiner's Office in the  
 regular course of business, and it was the regular course of business of the Dallas  
 County Medical Examiner's Office for an employee or representative, or a doctor  
 permitted to practice in the Dallas County Medical Examiner's Office, with personal  
 knowledge of the act, event, condition, opinion or diagnosis, recorded to make the  
 record or to transmit information thereof to be included in such record; and the  
 record was made at or near the time or reasonably soon thereafter. The records  
 attached hereto are the original or exact duplicates of the original.



SWORN TO AND SUBSCRIBED before me on the 30th day of December,  
1986.

Rosa Maria Suarez  
 Notary Public in and for DALLAS County, Texas

My commission expires 11/10/90

(By statute, the original records are retained by the Dallas County Medical Examiner's  
 Office. See Art. 49.25, Sec. 11, Vernons Texas Statutes, CCP.)

SOUTHWESTERN  
INSTITUTE OF FORENSIC SCIENCES  
AT DALLAS

5230 Medical Center Drive  
Dallas, Texas 75235

Case No. 3019-86-1413

Name: GRAF, Jason Cory

Age: 8

Race: White

Sex: Male

Date of Death: August 26, 1986  
Time of Death: Approx 5:00 P.M.

Date of Examination: September 11, 1986  
Time of Examination: 1:30 P.M.

Pronounced at: 505 Angelfire (backyard)  
Hewitt, McLennan County, Texas

AUTOPSY REPORT:

ORGAN WEIGHTS:

Brain	450 g
Heart	120 g
R. Lung	140 g
L. Lung	160 g
Liver	360 g
Spleen	NW
R. Kidney	NW
L. Kidney	NW

EXTERNAL EXAMINATION:

Clothing on body: None.

Accompanying body:

1. Request for exhumation and autopsy from G. Patrick Murphy and order for exhumation and autopsy from John Cabaniss, Justice of the Peace, Precinct 1, Place 1, McLennan County, Texas; photocopy of authorization for exhumation and autopsy from Clare Graf; release directed to Oakwood Cemetery for release of the body of Jason Graf, signed by John Cabaniss, Justice of the Peace; request for inquest, signed by Joseph D. Porter.
2. Joseph Porter, State Fire Marshall; Frank Latham and Rick Colwell of Hewitt Police Department; Wes and Tim Dixon from Connally-Compton Funeral Home.
3. White high pile, clothing covered casket containing dried dark rose and toy dog and white blanket; Free-Safe granules; black disaster pouch containing body.
4. Dallas County Medical Examiner case #3020-86 in similar casket.
5. Autopsy specimens from Dr. Northcutt consisting of plastic container marked "autopsy specimen OP86-28 Dr. Northcutt 8/27/86 Jason Graf," and slide tray containing five glass microscopic slides marked "OP86-28 one through five".
6. No jewelry.

The body is that of a normally developed, normally nourished white male child whose appearance is consistent with a stated age of eight years and eight months. The body is of average build. The body is 52 inches long, 132 cm, approximately 55th percentile for age. The remains weigh 42 lb, 19 kg, much less than 5th percentile for age but are consistent with a weight between 55 and 60 lb during life. Rigor mortis is replaced by a partially pugilistic pose. Livor mortis is not identified. The body is room temperature in the absence of refrigeration and in fair preservation in the presence of embalming granules.

Name: GRAF, Jason Cory

Case No: 3019-86-1413

Scalp hair is brown and slightly wavy, 2 inches long. The facial hair is not prominent. The eyes are tightly closed. The conjunctivae are cloudy. The ears, nose, and mouth are unremarkable. The teeth are natural and in good repair. The neck, trunk, and extremities have no significant abnormalities. The genitalia are those of a prepubertal male and are unremarkable. Body hair is of sparse amount, as is appropriate for the stated age. No significant scars are identified.

**EVIDENCE OF INJURY:**

1. Smoke inhalation. The body is soot covered. Soot is noted at the nares and mouth. Internal examination reveals soot in the distal airways, as well as in the larynx and trachea, preserved in the autopsy specimen container marked "OP86-28" for Jason Graf. Black to brown foreign material resembling soot is identified in the microscopic slides with similar case number.
2. Thermal burns. Most of the skin of the head, trunk, and extremities is burned brown to black with slight preservation of the skin on the left side in the bathing trunk clothing area and on the left buttock. Some of the skin is burned away and the bone is exposed at the right elbow. The skin is more extensively split over the right leg and the medial aspect of the left leg, which is held in extension. The internal organs are slightly heat damaged on the anterior surfaces of the lungs and heart.
3. No other injuries are identified.

**EVIDENCE OF MEDICAL ATTENTION:**

1. No evidence of resuscitation is identified.
2. A previous autopsy has been performed, including the chest and abdomen. The sections are reviewed and contain no abnormalities other than the above noted injuries. The granular preservative material is present and pungent to irritating. It has partially preserved most of the organs replaced in the cavities.

**INTERNAL EXAMINATION:**

**HEAD:** Other than the previously noted burning with exposure of part of the skull, the head is intact. The brain is softened but otherwise unremarkable.

**NECK:** Described under Injuries.

**SEROUS CAVITIES:** Opened during autopsy and organs replaced, otherwise unremarkable.

**CARDIOVASCULAR SYSTEM:** The heart is fixed in a collapsed state. It is tan-brown and otherwise unremarkable. The distal aorta contains no fatty streaks and is unremarkable.

**RESPIRATORY SYSTEM:** Part of the lung tissue is partially fixed and retains the dark red congested blood, as well as focal areas of soot in the distal airways, as described above. The lungs are otherwise unremarkable.

Name: GRAF, Jason Cory

Case No: 3019-86-1413

**GASTROINTESTINAL SYSTEM:** The stomach is not identified. The remainder of the gastrointestinal tract is collapsed and unremarkable. The appendix is present.

**HEPATOBIILIARY SYSTEM:** The liver is brown and contains some decomposition cysts. It is otherwise unremarkable. The gallbladder contains decomposition gas and no bile. Some sections of spleen and kidneys are identified in the autopsy specimen container and are unremarkable, as is the pancreas.

**MUSCULOSKELETAL SYSTEM:** Other than the acute injuries described, no pre-existing disease or injury are identified.

**MICROSCOPIC EXAMINATION:**

**Esophagus:** Black/brown material in lumen near mucosa.

**Trachea:** Black/brown foreign material consistent with soot at and on mucosa.

**Trachea:** Large amount of black/brown foreign material in lumen.

**Lung:** Black/brown material in bronchioles including mucus plug and in alveoli. Congestion. Edema.

**Liver:** Unremarkable.

**Lymph Node at Trachea:** Congestion with intermittent interstitial hemorrhage.

**Kidney:** Unremarkable except for slight congestion.

**Pancreas:** Mild autolysis.

Name: GRAF, Jason Cory

Case No: 3019-86-1413

**FINDINGS:**

1. Smoke inhalation with:
  - a. Soot on surface of body, nose, and mouth.
  - b. Soot in larynx, trachea, and distal airways.
2. Thermal burns involving head, trunk, and extremities with:
  - a. Modified pugilistic pose and more extensive burns of right side of body, preservation of back and left side under briefs.
3. Previous autopsy.
4. Mild to moderate postmortem decomposition with partial preservation by granular embalming material.

**CONCLUSION:**

It is our opinion that Jason Cory Graf, an eight year and eight month old white male child, died as the result of smoke inhalation and thermal burns. He was positively identified by comparison of postmortem x-rays and premortem dental x-rays obtained from Steven Cutbirth, D.D.S., 1613 Lake Success, Waco, Texas. By history the fire in which he died was of incendiary origin. Postmortem toxicology revealed brompheniramine in the liver.

**MANNER OF DEATH:** Homicide.

COPY

*M.G.F. Gilliland*  
M.G.F. Gilliland, M.D.  
Medical Examiner

*James Weiner*  
James Weiner, M.D.  
Medical Examiner

*P.E. Besant-Matthews*  
P.E. Besant-Matthews, M.D.  
Deputy Chief Medical Examiner

*Charles S. Petty*  
Charles S. Petty, M.D.  
Chief Medical Examiner

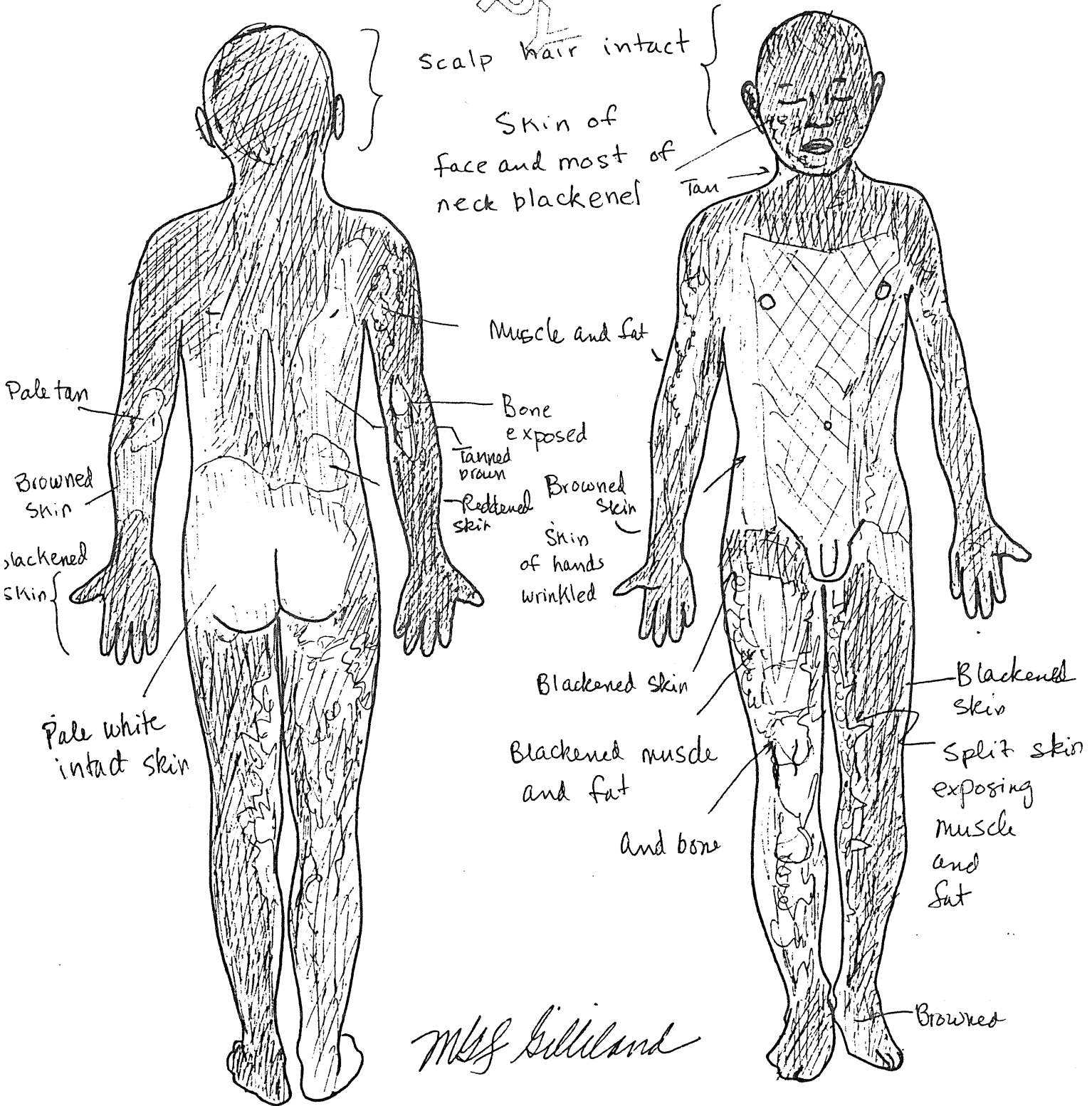
**TOXICOLOGY:**

Lung: Negative for volatiles

Liver: Negative for volatiles  
Alkaline screen - 0.52 mg/L brompheniramine  
AN drug screen - negative

Protocol typed by Annette Bryant

COPY



Mrs. Gilliland